

Stress fractures of the os capitate: apropos of a case

CARLES PEDRET CARBALLIDO^{a,b,c}, GIL RODAS FONT^{d,e}, ASUN ESTRUCH^f, IGNACIO QUIXANO^g AND ALEIX BORRÀS^g

^aSchool of Sports Medicine, University of Barcelona. Barcelona. Spain.

^bTarragona Basketball Club. Tarragona. Spain.

^cClub Bàsquet Valls. Valls. Tarragona. Spain.

^dBarcelona Football Club Medical Service. Barcelona Spain.

^eMedical Service for the Spanish Royal Field Hockey Association. Barcelona Spain.

^fDepartment of Catalan Sports. Government of Catalonia. Barcelona. Spain.

^gPhysiotherapy Service. Open Sánchez-Casal Tennis Academy. Barcelona. Spain.

ABSTRACT: Traumatic or stress fractures of the os capitate are highly uncommon findings in clinical practice. These fractures should be suspected in insidious and persistent pain in the palm of the hand in persons with high demand on this extremity or repeated trauma. This article presents the case of a 16-year-old female tennis player with a 6-month history of selective pain in her right hand.

KEY WORDS: Stress fractures. Os capitate. Tennis.

RESUMEN: Las fracturas traumáticas o por estrés del hueso grande del carpo (*os capitate*) son hallazgos realmente infrecuentes en la práctica clínica. Son una entidad que se debe sospechar ante un dolor insidioso y persistente en la palma de la mano en personas con una elevada demanda de esta extremidad o con traumatismos repetidos. En este artículo se presenta el caso de una jugadora de tenis de 16 años con dolor selectivo en la mano derecha de meses de evolución.

PALABRAS CLAVE: Fracturas de estrés. Hueso grande. Tenis.

INTRODUCTION

A 16-year-old tennis player complaining of pain in the palm of her hand over a five month period. She is right-handed. The patient was initially diagnosed with tendinopathy of the hand flexors and underwent conventional rehabilitation treatment. The patient combined her training schedule with physiotherapy for two months. During this period, the pain returned with the same intensity while playing sport.

Given the persistence of the pain, the patient sought treatment at this medical service. The pain increased on palpation of the tip of the carpus finger, particularly in the central part of the hand and a delicate area was located on the palm aspect of the capitate bone. Furthermore, the pain increased during forced dorsiflexion of the wrist. The patient related the said pain with continued excess load along the distal and lateral edge of the racket handle on the palm of the hand (fig. 1.)

Due to the prolonged evolution of the lesion, magnetic resonance (MR) was performed. This showed an image suggesting a trabecular fracture of the right capitate bone with slight leakage and synovitis of the extensor tendons (fig. 2.) A scan (CT) was also performed. This showed a non-displaced fracture on the palmar aspect of the middle third of the capitate bone, with no fragment displacement (fig. 3.)

Given the rare nature of the lesion, the study was completed with a bone gammagraphy (fig. 4.) This showed active osteogenic phenomena secondary to the known fracture of capitate bone on the right hand.

The patient was told to refrain from sport for six weeks, after which they would progressively ease back into their normal sporting activity under strict

Article history: Received on 1 January 2009 / Approved on 19 January 2009.

How to cite this article: Pedret C, Rodas G, Estruch A, Quixano I, Borràs A. Fractura de estrés del hueso grande del carpo: a propósito de un caso. *Apunts Med Esport*. 2009;161:38-41.

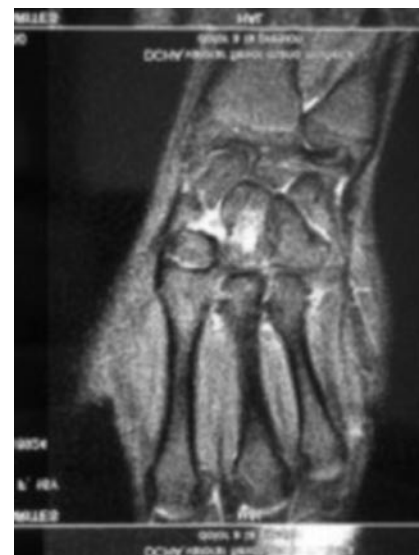Correspondence to: Carles Pedret (drpedret@gmail.com).

Figure 1

Image of the tennis racket grip.

**Figure 2**

The MR image shows the trabecular fracture of the capitate bone.



supervision, in particular in relation to any pains or discomfort they may experience.

DISCUSSION

Traumatic or stress fractures of the capitate bone (*os capitate*) are extremely rare in clinical practice (1-3% of all carpus fractures).¹⁻³ Traumatic fracture lesions of the capitate bone are usually caused by a fall, with forced hyperextension of the wrist and cubital or neutral deviation or direct contusion of the dorsal aspect of the wrist. Stress fractures may be caused by repeated forced dorsiflexion of the wrist with repeated trauma on the palmar aspect of the hand.^{2,4} In this respect, the aetiopathogeny of the stress fracture of the capitate bone is similar to that described for stress fracture of the hook of the hamate.^{5,6}

Clinical suspicion is fundamental in diagnosing this type of fracture of the

capitate bone, since it enables further and more appropriate tests to be requested for the definitive diagnosis. Simple radiology does not always detect the lesion caused by stress of the capitate bone⁷ and it is often necessary to request a scan and/or MR to confirm the diagnosis,^{7,8} leaving the bone gammagraphy for doubtful cases or to control evolutionary activity.^{9,10}

While this type of fracture normally evolves correctly with conservative treatment and rest and immobilisation for six weeks,^{4,7,8} the surgical option of internal fixation is reserved for cases of nonunions, displacement or pseudarthrosis.¹¹

Another factor to be taken into account with regard to fractures of the capitate bone, regardless of whether these are traumatic or stress fractures, is its weak circulatory supply and the possibility of causing avascular necrosis similar to that in the scaphoid bone. The blood vessels in the capitate bone

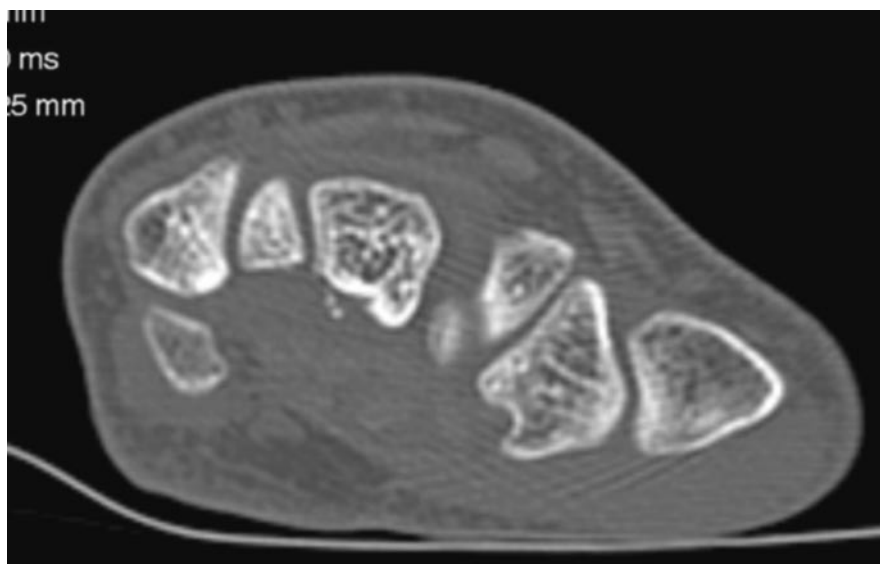
have longitudinal distal-to-proximal flow and this reversed flow causes the risk of avascular necrosis in the capitate bone. Likewise, poor revascularisation following a fracture can also lead to delayed union.^{12,13} The tennis player in this study did not have this problem since the fragment (palmar) was not large enough for delayed union to present clinically.

Playing top level sport causes excess load, particularly on the joints which are most frequently used depending on the sport.¹⁴ In our study, tennis causes repeated excess load, particularly on the wrist and hand, which is associated to minor but repeated traumas in this area. The sports medicine specialist must always take this into account when evaluating pain in the hand, in particular if the pain is centred in the central area of the palm of the hand.

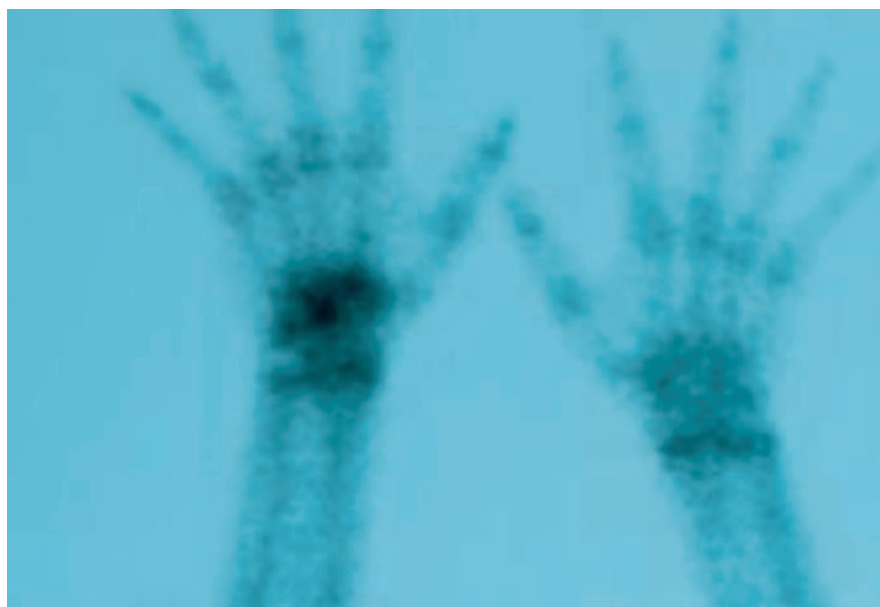
With respect to risk factors for stress fractures in general, patient sex and age

Figure 3

CT showing image of the non-displaced fracture on the palmar aspect of the third middle of the capitate bone.

**Figure 4**

The bone gammaigraphy shows hyper-uptake in the right carpus.



must be taken into account, since being a woman and young causes a certain predisposition to fractures due to excess load.¹⁵ For the case in question, despite the fact that the patient presented a normal menstrual pattern, these factors added to the increased workload and/or repeated dorsiflexion movements in the wrist.

CONCLUSION

Stress fractures of the capitate bone are a clinical entity that must be suspected in cases of insidious and persistent pain in the palm of the hand in persons with a high demand on this extremity or repeated traumas. If a stress lesion is suspected in the palm of the hand, MR is the preferred test to be performed. In the absence of complications, such as displacement or delayed union, treatment is normally conservative, with immobilisation and rest for approximately six weeks. After this period, the sportsperson must be progressively eased back into their training workload, always asymptotically.

References

1. Allen H, Gibbon WW, Evans RJ. Stress fracture of the capitate. *J Accid Emerg Med.* 1994;11:59-60.
2. Vizkelety T, Wouters HW. Stress fracture of the capitate. *Archivum chirurgicum Neerlandicum.* 1972;24:47-57.
3. Rand JA, Linschield RL, Dobyns JH. Capitate fractures. A long term follow up. *Clin Orthop.* 1982;165:209.
4. Alder GW, Shafon JB. Fractures of the capitates. *JBJS.* 1962;44A:1537.
5. Ardèvol Cuesta J. Fractura de estrés y retardo de consolidación de la apófisis unciforme del hueso ganchudo. Caso clínico en un jugador de hockey hielo. *Apunts. Medicina de l'esport.* 1999;34: 37-8
6. Stark HH, Jobe FW, Boyes JH, et al. Fracture of the hook of the hamate in athletes. *J Bone Joint Surg.* 1977;59A: 575-82.
7. Albertsen J, Mencke S, Christensen L, et al. Isolated capitates fracture diagnosed by computed tomography. Case report. *Handchir Mikrochir Plast Chir.* 1999; 31:79-81.
8. Calandruccio JH, Duncan SF. Isolated nondisplaced capitate waist fracture diagnosed by magnetic resonance imaging. *J Hand Surg (Am).* 1999;24: 856-9.
9. Hopkins W, Amman SR. Isolated fracture of the capitate – use of nuclear medicine as an aid to diagnosis. *Int J Sports Med.* 1990;11:312.
10. Yoshihara M, Sakai A, Toba N. Nonunion of the isolated capitate waist fracture. *J Orthop Sci.* 2002;7:578-80.
11. Neville W, O'Donnell M, Neill S. Internal fixation of an isolated fracture of the capitate using the Herbert-Whipple screw. *Int J Care Injury.* 2004;35: 540-1.
12. Freedman DM, Botte MJ, Gelberman RH. Vascularity of the carpus. *Clin Orthop.* 2001;383:47-59.
13. Panagis JS, Gelberman RH, Taleisnik J, et al. The arterial anatomy of the human carpus. Part II: The intraosseous vascularity. *J Hand Surg Am.* 1983;8:375-82.
14. Roca J, Cabot J. Fracturas por sobrecarga en el deportista. *Apunts. Medicina de l'esport.* 1985;23:17-24.
15. Zinder R, Koester M, Duna W. Epidemiology of stress fractures. *Clin Sports Med.* 2006;25:37-52.